

# Intermediate Crural Overlay in Rhinoplasty

## *A Deprojection Technique That Shortens the Medial Leg of the Tripod Without Lengthening the Nose*

Jeffrey B. Wise, MD; Samuel S. Becker, MD, MFA; Anthony Sparano, MD; Jacob Steiger, MD; Daniel G. Becker, MD

**Objective:** To review the indications for, surgical techniques of, and results of intermediate crural overlay of the alar cartilages in rhinoplasty.

**Design:** Prospective study of patients undergoing intermediate crural overlay of the lower lateral cartilages. The setting was a facial plastic surgery private practice. Patients included 10 primary rhinoplasty patients and 1 revision rhinoplasty patient who underwent intermediate crural overlay of the lower lateral cartilages. The main outcome measures were postoperative photographs and patient records, which were reviewed for tip projection and rotation, preservation of the double break, bossae, and knuckling.

**Results:** Intermediate crural overlay decreased projection in all 11 patients and increased the nasolabial angle in 7 patients. One patient had no change in the nasola-

bial angle, and 3 patients had counterrotation of 1°, 3°, and 4°. A postoperative physical examination revealed that no patient had developed bossae, tip asymmetries, or knuckling. In addition, the double break was maintained in all the study patients.

**Conclusions:** Intermedial crural overlay is a reliable technique for achieving tip deprojection. Overall, the nasolabial angle is maintained (although in 3 patients, clinically insignificant counterrotation did occur). In addition, the length of the intermediate crura is reduced, but the double break is preserved. In the group of patients with thin skin and tip overprojection secondary to overdevelopment of the lower lateral cartilages, intermediate crural overlay achieves tip deprojection while controlling the nasolabial angle and preserving the natural curvature of the dome.

*Arch Facial Plast Surg. 2006;8:240-244*

**Author Affiliations:** Division of Facial Plastic and Reconstructive Surgery, Department of Otorhinolaryngology–Head and Neck Surgery, University of Pennsylvania Medical Center, Philadelphia (Drs Wise, Sparano, Steiger, and D. G. Becker); and Department of Otolaryngology–Head and Neck Surgery, University of Virginia Medical Center, Charlottesville (Dr S. S. Becker). Dr D. G. Becker is also in private practice in Sewell, NJ.

**T**HE ANATOMICAL FEATURES of the lower lateral cartilage (LLC) have been well described.<sup>1,2</sup> The LLCs can be described as having a lateral crus, an intermediate crus, and a medial crus. The intermediate crus begins at the anterior aspect of the medial crus and flares posteriorly and laterally to become the lateral crus. This configuration of the intermediate crus is responsible for the “double break.” Anatomical studies and experience have taught the rhinoplasty surgeon about the tremendous variability in the shape, size, and strength of the LLCs and about their individual components.

We have identified a subset of patients with overprojection secondary to overdevelopment of the intermediate crura. In these patients, vertical intermediate crural overlay (ICO) has proved to be an effective approach. This is accomplished by division of the LLCs at the junction of the intermediate crura and medial crura, with dissection to free the intermediate crura from the underlying vestibular mucosa. This allows overlap of the intermediate and me-

dial crura with precise calibrated deprojection. The nasolabial angle is maintained, so there is no counterrotation. The length of the intermediate crura is reduced, but the double break is maintained, so there is no illusion of counterrotation. Intermediate crural overlay avoids vertical dome division (VDD), which is desirable in certain patients for technical reasons.

Surgical techniques available for the treatment of the overprojected nasal tip include full transfixion incision, dome division with excision of a portion of the LLC, excision of an overdeveloped nasal spine, excision of overdeveloped medial crural footplates, and others.<sup>2</sup> These techniques cannot be applied generically; to achieve successful deprojection, the surgeon must select the technique or techniques that are appropriate to the specific anatomical cause for overprojection.

As demonstrated in this report, the intermediate crura can be shortened to achieve deprojection without causing counterrotation. Furthermore, the configuration of the intermediate crura (ie, the posterior and lateral flaring of the inter-

mediate crura) can also be maintained while performing ICO. This preserves the “illusion” of rotation that is due to the double break.

## METHODS

### INDICATIONS FOR ICO

In conjunction with other rhinoplasty techniques, ICO may be a useful technique for achieving tip deprojection. It seems to be ideal for thin-skinned patients with tip overprojection secondary to overdevelopment of the LLCs, specifically, the intermediate crus. Although VDD is one potential approach, we believe that an alternative technique may be preferable in thin-skinned patients. In an effort to preserve the natural contour of the dome without risking the development of visible cartilage edges, ICO is used. Furthermore, ICO preserves the preoperative nasolabial angle and avoids significant counterrotation.

### TECHNIQUE

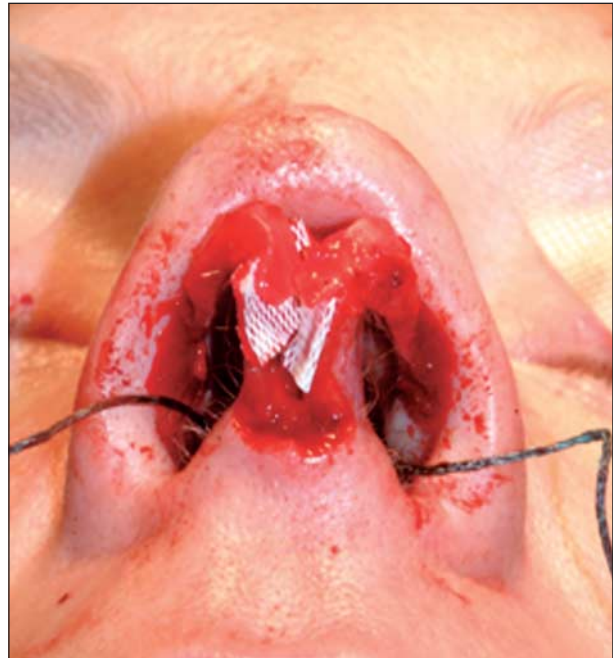
While the authors believe that an external rhinoplasty approach offers advantages when performing this technique, ICO may also be performed using a tip delivery approach. Other aspects of the rhinoplasty are performed as appropriate. With the tip cartilages exposed, dissection is undertaken between the medial and intermediate crura (**Figure 1**). Division of the cartilages is undertaken bilaterally at the junction between the medial and intermediate crura. The vestibular skin is dissected off of the intermediate crura, and the intermediate crura are overlapped with the medial crura. The intermediate crura are medial to their respective medial crura. Suture reapproximation is undertaken with a 5-0 polydioxanone suture. A columellar strut may be placed if needed. However, the overlapped cartilages often act as a strut and make the additional placement of a columellar strut unnecessary. Great care is taken to maintain the orientation of the intermediate crus so that the double break is maintained.

In no patient were tip grafts used. Most of these patients possessed thin skin and, hence, the operating surgeon (D.G.B.) believed that tip grafts were relatively contraindicated. All patients underwent domal and interdomal suturing in a manner described by Papel,<sup>3</sup> using a 5-0 polydioxanone mattress suture. These sutures were centered over the dome, and were specifically placed so as not to achieve rotation or counterrotation. Domal suturing was undertaken after ICO, and intraoperative evaluation revealed no need for rotation, although if it had been necessary, this would have been an option. In addition, based on the preoperative evaluation, 3 patients underwent alar base narrowing.

## RESULTS

Eleven patients who underwent open septorhinoplasty, performed by one of us (D.G.B.), were included in this study from January 1, 2001, through June 1, 2005. There were 9 females and 2 males (mean age, 30.2 years; age range, 16-45 years). Ten patients underwent a primary rhinoplasty and 1 patient underwent a revision rhinoplasty. All patients who underwent this technique during the study period were included in the study.

In the context of preoperative analysis, all patients had overprojected tips. Of the 11 patients, 8 had thin skin and 3 had medium thickness skin. No patients were judged to have thick skin. In addition, the patients in the study group



**Figure 1.** Intraoperative photograph demonstrating the intermediate crural shortening technique. A nasal dressing (Telfa) was placed beneath the 2 cut segments of cartilage to illustrate the position of the incision at the intermediate crura.

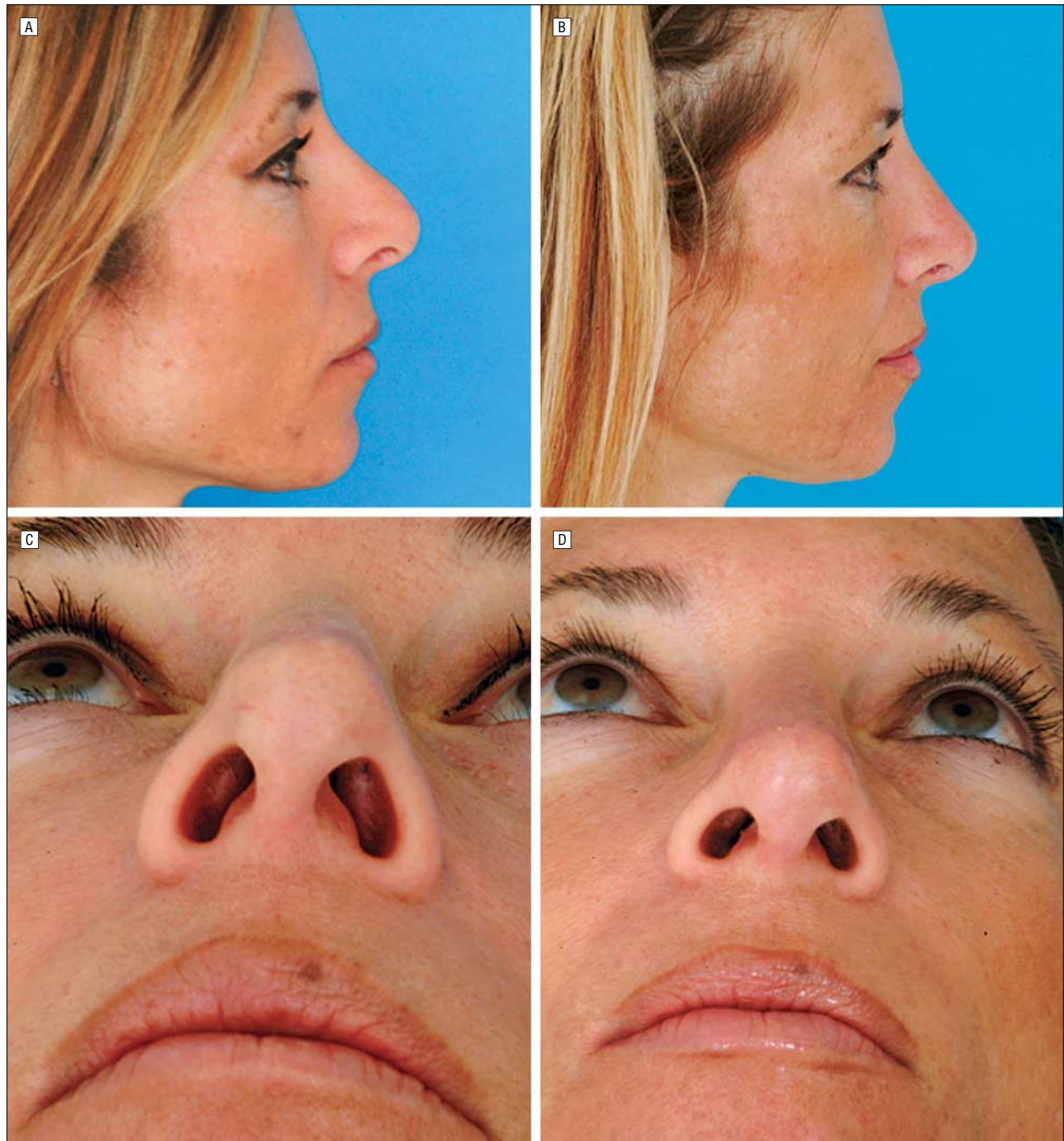**Table. Comparison of Preoperative With Postoperative Nasolabial Angles Following Intermediate Crural Shortening\***

Patient No.	Nasolabial Angle, °		Difference Between Preoperative and Postoperative Nasolabial Angles, °
	Preoperative	Postoperative	
1	113.0	110.0	-3.0
2	108.0	117.0	9.0
3	105.0	107.0	2.0
4	114.5	118.0	3.5
5	113.0	113.0	0.0
6	113.0	112.0	-1.0
7	112.0	114.0	2.0
8	108.0	110.0	2.0
9	110.0	112.5	2.5
10	100.0	96.0	-4.0
11	109.0	111.5	2.5

\*For the 11 patients, the mean (SD) crural shortening was 1.41° (3.33°); the median crural shortening was 2.00°.

possessed identifiable, but not overly exaggerated, columellar double breaks, representing a satisfactory junction of the medial and intermediate crura of the LLCs.

Intermediate crural overlay was performed in all 11 patients. Other aspects of rhinoplasty were performed where indicated. Follow-up ranged from 2 months to 3 years (mean, 14.4 months). In all patients, tip deprojection was achieved by ICO only. Preoperative and postoperative nasolabial angles were measured by an observer (J.S.) who was blinded to the study objectives (**Table**). Cephalad rotation of the tip was noted in 7 of the 11 patients, and caudal rotation of the tip was noted in 3 of the 11 patients. No measurable difference in preoperative and postoperative nasolabial angles was ob-



**Figure 2.** Preoperative (A and C) and postoperative (B and D) photographs demonstrating deprojection of the nasal tip after intermediate crural shortening. Lateral (A and B) and base (C and D) views are shown.

served in 1 of the 11 patients. Postoperatively, no patients have developed bossae, tip asymmetries, or knuckling. In addition, the double break was maintained in all study patients (**Figure 2**). No patient in this study has required revision.

#### COMMENT

The tripod concept is a well-established teaching tool that helps residents and other surgeons understand the basic principles governing techniques to achieve surgical

rotation or counterrotation, as well as projection or deprojection of the nasal tip. However, the tripod concept is a simplification; there are subtleties of tip dynamics that the tripod concept does not accurately explain. For example, the tripod concept teaches that shortening of the leg of the tripod comprising the medial and intermediate crura results in deprojection and counterrotation. The clinical experience described herein suggests otherwise.

Several techniques exist to achieve deprojection. Each is designed to address a specific anatomical cause, and each is generally effective when the anatomical cause of

a patient's tip overprojection is properly identified. For example, when a patient has a large nose, such as in a tension nose deformity, the tip is held in an overprojected position because of its attachments to the overdeveloped nose. In this situation, releasing these attachments and reducing the overdeveloped hump result in repositioning of the nasal tip. Little else is required to achieve the desired deprojection.

In an occasional patient, overdevelopment of the nasal spine is encountered, and reduction of this will result in some deprojection. However, this is an occasional cause and is not a primary technique for deprojection. While the literature describes cephalic resection as an approach for causing deprojection and rotation, the effect is subtle.

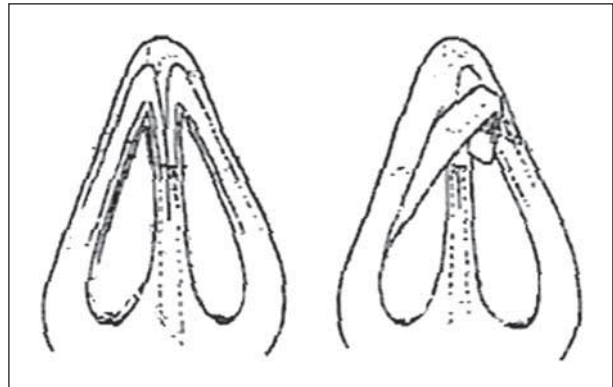
Several patients with overprojection of the nasal tip have overdevelopment of the tip cartilages themselves. In these patients, it is not enough to simply release attachments—the tip cartilages themselves must be addressed.

One option is VDD, described by Goldman<sup>4</sup> in the 1950s. By resecting LLC medial and lateral to the tip-defining points, deprojection is achieved. Some researchers advocate suture reapproximation, while others believe that this is not necessary. The literature is nearly unanimous that, in the setting of VDD, cephalic resection should be extremely conservative.<sup>5,6</sup> In the anatomical setting of overdeveloped LLCs, VDD is an effective technique of deprojection. However, like all techniques, it carries certain risks. In thin-skinned patients, there is the risk that VDD will result in visible and unsightly edges. Also, VDD has been associated in some reports with bossae formation. For those surgeons who believe that these risks are of significant concern, an alternative approach that mitigates these risks would be useful in their armamentarium.

Treatment of the subset of patients described in this report requires reduction in the size of the alar cartilages. In this group of patients with thin skin and overprojection secondary to overdevelopment of the LLCs (specifically, the intermediate crus of the LLC), it has been the authors' preference to preserve the natural curvature of the dome to avoid VDD and mitigate the risks previously described.

Techniques that deproject the nose while preserving the structural integrity of the domal unit have been described in the literature as early as the 1930s.<sup>7</sup> More recently, Kridel and Konior<sup>8</sup> described a lateral crural overlay technique that deprojects the nose while rotating a ptotic tip. Foda<sup>9</sup> has described an alar setback technique whereby the medial and lateral crura are shortened in patients with overprojected nasal tips secondary to overdevelopment of the alar cartilages. In his series,<sup>9</sup> the lateral crura were overlapped and sutured, and segments of the medial crura were excised and splinted with a columellar strut.

Constantinides et al<sup>10</sup> describe the technique of vertical lobular division used by the authors, in which the LLCs may be divided at the lateral crura, the domes, or the medial crura, depending on the surgical objective. The researchers<sup>10</sup> indicate that division around the intermediate crura–medial crura junction causes counterrotation, and that measures must be taken to counteract this if counterrotation is not desired.



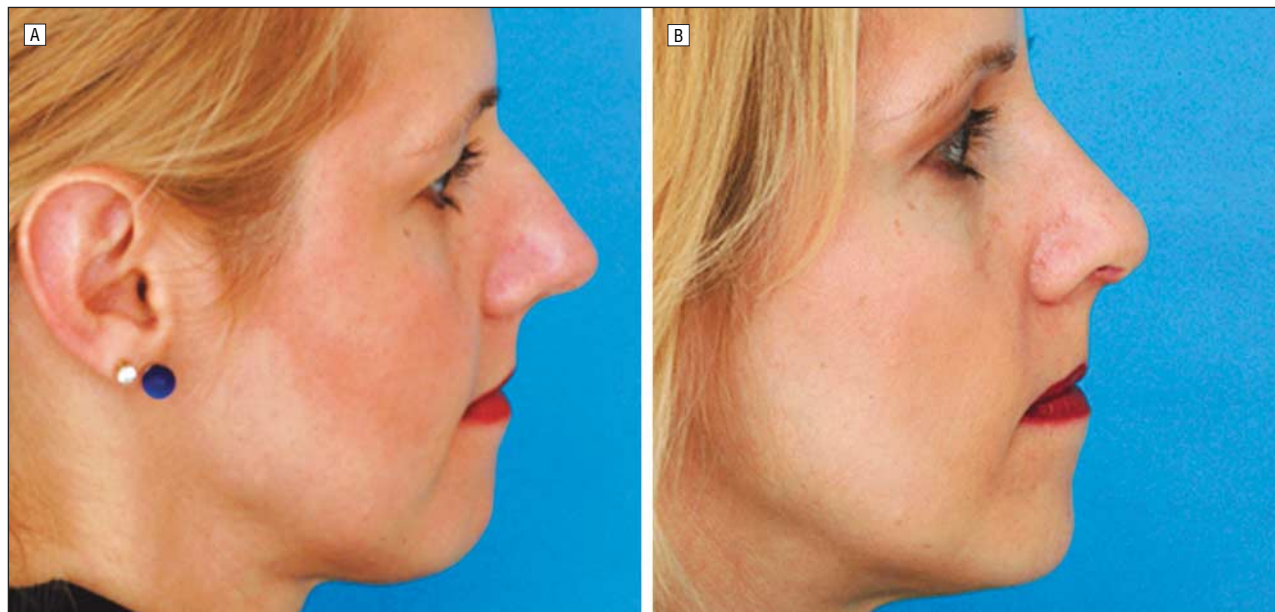
**Figure 3.** Splitting incision at the level of the intermediate crura, as described by Lipsett.<sup>12</sup>

Similarly, Soliemanzadeh and Kridel<sup>11</sup> have published an algorithm of surgical deprojection techniques, including medial crural overlay, for the treatment of nasal tip overprojection. In their algorithm, the researchers<sup>11</sup> base their deprojection techniques on several preoperative variables, including the position of the radix, the presence or absence of a tension septum, skin thickness, and tip rotation.

Intermediate crural overlay is not a new technique. In 1959, Lipsett<sup>12(p42)</sup> described a “novel approach to the lower cartilaginous vault,” whereby the medial crura are incised at the level of the dorsum and delivered. Shortening and scoring of the medial and intermediate crura allow for more optimal control of postoperative outcomes. In addition, he emphasized the importance of preserving the lateral crura, dome, and part of the medial crura as a unit for more predictable results. With no interruption of the cartilage at the dome, possible deformities at the most prominent part of the nose are precluded. Lipsett<sup>12</sup> advocated the use of this technique for deprojecting noses, along with precisely altering nasal tip rotation in either the cephalad or caudal direction (**Figure 3**).

In selected patients with overdevelopment of the intermediate crura, we believe the term *intermediate crural overlay* is most appropriate in describing the technique presented herein. Indeed, the intermediate crura are overlaid. Others have had similar findings, eg William Silver, MD, unpublished 20-year experience with the “medial crural tuck-up,” April 2005. This unpublished approach is identical to the approach described herein in its treatment of the alar cartilages at the junction of the medial and intermediate crura. This approach is beneficial in the patient with overprojection and thin skin. However, Silver believes that this aspect of the procedure causes counterrotation; to address this, he also excises or overlaps the lateral crura an identical amount that he overlaps the medial and intermediate crura.

In the present series, 7 of the 11 patients had postoperative rotation and 1 patient had no change in the nasolabial angle. Three patients had a small degree of operative counterrotation that was of minimal clinical significance. These patients' preoperative and postoperative nasolabial angles were within the normal values defined by the “aesthetic ideal.” Also, the authors have found that with experience, this technique affords the surgeon the ability to con-



**Figure 4.** Preoperative (A) and postoperative (B) photographs demonstrating how overlapping of the medial and intermediate crura acts to “plump” the columella.

control the double break—to soften it, to maintain it, or to make it more prominent, as indicated.

The authors have also found that overlapping of the medial and intermediate crura acts to “plump” the columella. This can be useful in patients with a hidden columella (**Figure 4**), but must be addressed by reducing the volume of the overlapped cartilage if this is an undesired effect.

While physical examination of the patients has revealed no bossae, knuckling, or other tip complications, we recognize that further follow-up will be required. However, cephalic resection was conservative when performed, and the natural domal configuration was preserved, so the risk of tip complications is expected to be minimal. In addition, while photographs were taken with good lateral views, some photographs were obtained with subtle differences in patient position, such as in Figure 4A and B. Such photographic error could lead to slight error in analysis, but we do not believe that this is significant with regard to the overall results and statistical analyses.

As with all surgical techniques, preoperative anatomical analysis is critical to the identification of the patient whose anatomical features lend themselves to this technique. A prominent and long double break in the presence of tip overprojection seems to be suggestive.

Surgeons select techniques for each rhinoplasty based on the patient’s unique anatomical features and based on consideration of each technique’s various effects. It seems that the tripod concept has led to the assumption that shortening of the medial crural leg of the tripod led to counterrotation of the nasal tip. The clinical experience described herein suggests otherwise. We suggest that, perhaps because of these assumptions, ICO has been underused. With this in mind, rhinoplasty surgeons may find this technique to be of increased use in their surgical armamentarium.

In conclusion, ICO is an effective technique when deprojection of the tip is desired without significant changes in

tip rotation. The double break seems to be maintained following ICO. In contrast to VDD, ICO preserves the dome. Especially for the thin-skinned patient with overprojection of the nasal tip, ICO is a useful technique in the armamentarium of the rhinoplasty surgeon.

**Accepted for Publication:** February 23, 2006.

**Correspondence:** Daniel G. Becker, MD, Becker Nose and Sinus Center, LLC, 400 Medical Center Dr, Suite B, Sewell, NJ 08080 (beckermailbox@aol.com).

**Previous Presentation:** This study was presented at the American Academy of Facial Plastic and Reconstructive Surgery Fall Meeting; September 25, 2005; Los Angeles, Calif.

## REFERENCES

1. Tardy ME. *Rhinoplasty: The Art and the Science*. Philadelphia, Pa: WB Saunders Co; 1997.
2. Toriumi DM, Becker DG. *Rhinoplasty Dissection Manual*. Philadelphia, Pa: Lippincott Williams & Wilkins; 1999.
3. Papel ID. Interlocked transdomal suture technique for the wide interdomal space in rhinoplasty. *Arch Facial Plast Surg*. 2005;7:414-417.
4. Goldman IB. The importance of the mesial crura in nasal-tip reconstruction. *AMA Arch Otolaryngol*. 1957;65:143-147.
5. Brennan HG. Dome-splitting technique in rhinoplasty with overlay of lateral crura. *Arch Otolaryngol*. 1983;109:586-592.
6. Kridel RWH, Konior RJ. Dome truncation for management of the overprojected nasal tip. *Ann Plast Surg*. 1990;24:385-396.
7. Safian J. *Corrective Rhinoplastic Surgery*. New York, NY: P Hoeber; 1935.
8. Kridel RWH, Konior RJ. Controlled nasal tip rotation via the lateral crural overlay technique. *Arch Otolaryngol Head Neck Surg*. 1991;117:411-415.
9. Foda HMT. Alar setback technique: a controlled method of nasal tip deprojection. *Arch Otolaryngol Head Neck Surg*. 2001;127:1341-1346.
10. Constantinides M, Liu ES, Miller PJ, Adamson PA. Vertical lobule division in rhinoplasty: maintaining an intact strip. *Arch Facial Plast Surg*. 2001;3:258-263.
11. Soliemanzadeh P, Kridel RWH. Nasal tip overprojection: algorithm of surgical deprojection techniques and introduction of medial crural overlay. *Arch Facial Plast Surg*. 2005;7:374-380.
12. Lipsett EM. A new approach surgery of the lower cartilaginous vault. *AMA Arch Otolaryngol*. 1959;70:42-47.